

UNIT OF AXIS JOURNALS

International Peer Reviewed Medical Journal Committed for Excellence

Kissing warts

Sheikh AS

Resident

Department of Medicine, King Edward Medical University & Mayo Hospital, Lahore, Pakistan

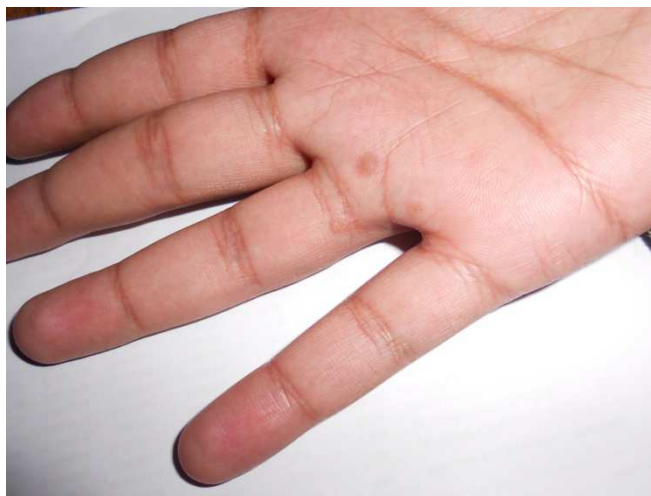
IMAGE

A 29 year old man developed three skin coloured lesions near his right ring finger. The first lesion was noticed in the teens and had persisted for a number of years before the other two appeared sequentially in late twenties. These warty lesions were painless and non-itchy. There was no relevant history of medical illness or regular medication usage. On palpation, they had a roughened surface. These warts are caused by human papilloma virus, and are prone to develop in proximity to each other, hence named the “kissing warts”. They are particularly stubborn to most forms of treatment including salicylic acid, cryotherapy, electrodesiccation and curettage. After carefully discussing different treatment options with the patient, he opted to apply De-wart lotion containing podophyllum emodi extract, verrugon and milk acid. Multiple applications were required and the warts decreased in size gradually. After four months of dedicated treatment, the patient was wart-free.

Received on 23 Oct 2014

Accepted on 30 Oct 2014

Published on 30 Nov 2014



Photograph showing multiple kissing warts

CORRESPONDENCE ADDRESS

Dr. Ali Sibtain Farooq Sheikh,
Resident, Department of Medicine,
King Edward Medical University & Mayo Hospital, Lahore,
Pakistan
Email: asfsheikh@gmail.com

Please cite this paper as: Sheikh AS. Kissing warts. Inter J
Medical Sci Res Prac 2014; 1 (3): 108.