

UNIT OF AXIS JOURNALS

International Peer Reviewed Medical Journal Committed for Excellence

**Urgent carotid endarterectomy for acute cerebral ischemia**

Bedi HS,<sup>1</sup> Pandian JD,<sup>2</sup> Gupta A<sup>3</sup>

Head CTVS,<sup>1</sup> Professor & Head Neurology,<sup>2</sup> Head Cardiac Anesthesia<sup>3</sup>

Department of Cardiovascular Endovascular & Thoracic Surgery,<sup>1</sup> Department of Neurology,<sup>2</sup>

Department of Cardio Vascular Anesthesia<sup>3</sup>

<sup>1-3</sup>Christian Medical College & Hospital, Ludhiana, Punjab, India

**ORIGINAL RESEARCH**

**ABSTRACT**

**Background**

Carotid endarterectomy (CEA) is well established as the elective treatment for severe symptomatic carotid stenosis. In contrast, the merits of CEA performed as an emergency procedure in patients with acute stroke or fluctuating neurological deficit remain controversial

**Material Methods**

CEA was performed as an emergency procedure on 16 patients within 4 to 48 hours after the onset of symptoms. Patients selected for urgent surgery fulfilled the following criteria: acute onset of fluctuating hemispheric neurological symptoms, significant carotid pathology, absence of cerebral hemorrhage, absence of massive cerebral damage and stable cardiopulmonary conditions. The patients presented with a crescendo-TIA in 7, evolving (stuttering) stroke in 3 and fluctuating neurological deficits in 6 - corresponding to a contralateral carotid stenosis.

**Results**

Following CEA, the neurological deficits improved instantaneously to complete recovery in 10 patients. The symptoms of 4 patients improved to non-disabling deficits, and remained unchanged in two patients. 14/16 patients were discharged within 8 days after admission. The neurologic status after discharge did not deteriorate in any of the patients during follow up - in fact it further improved in 4 of the patients (2 in whom there had been no change and 2 in whom there had been a partial improvement).

**Conclusion**

Emergency CEA may be beneficial for selected patients with stroke in evolution and fluctuating neurological deficits. Careful adherence to selection criteria, judicious intraoperative shunting, intensive unit care post surgery and an experienced team are recommended.

**Key Words**

Carotid endarterectomy, Crescendo TIA, Stroke in evolution

Received on 11 Oct 2014

Accepted on 26 Nov 2014

Published on 30 Nov 2014

**INTRODUCTION**

Carotid endarterectomy (CEA) is a proven effective therapy for the elective treatment of severe symptomatic carotid stenosis as has been demonstrated in several randomized, prospective clinical trials.<sup>1,2</sup> On the other hand, delay in endarterectomy exposes the patient to a 2 - 21% risk of recurrent stroke<sup>3,4</sup> making a case for early CEA. However indications for emergency CEA in patients with acute neurological symptoms are still controversial. The early experiences in the treatment of 'acute' carotid artery stenosis were described in the 1960s and were characterized by poor results, mainly due to postoperative intracranial

hemorrhage<sup>5,6</sup> into the ischemic infarction area. As a consequence, in the following years the avoidance of urgent CEA was commonly accepted worldwide and the intervention was generally delayed for 4-6 weeks after the clinical event.<sup>7</sup> However in most of the earlier studies a preoperative Computed Tomographic (CT) scan was not done to rule out preexisting hemorrhage and intensive care unit (ICU) care in relation to blood pressure control was not available.<sup>5,6</sup> In recent years - with significant improvements in surgical, medical and anesthesia techniques, and the creation of specialized departments taking care of acute stroke patients - there has been a rising interest in the

surgical treatment of patients with unstable neurological symptoms. Recent studies have emphasized the safety and the acceptable perioperative stroke or mortality rate after early CEA in patients after non-disabling stroke or acute neurological events.<sup>8,9</sup>

## MATERIAL AND METHOD

CEA was performed as an emergency procedure on 16 patients within 4 to 48 hours after the onset of symptoms. Two patients were operated upon in Christian Medical College & Hospital, Ludhiana, Punjab, India and 14 in Ludhiana Mediciti Hospital, Ludhiana, Punjab, India. The protocol and informed consent were approved by the Institutional Review Board and all subjects gave informed consent for the emergency surgery. Preoperative diagnostic procedures consisted of a detailed documentation of the patient's medical history, a neurological and vascular examination, duplex ultrasound, and CT angio scan of the brain with contrast medium and a Magnetic Resonance (MR) study for evaluation of cerebral parenchyma and supra aortic vessels. The status of the vertebral arteries, the intra cranial vessels and the circle of Willis was also specifically looked for in the angiograms. All patients gave their informed consent prior to surgery. General patient characteristics are summarized in Table I.

Table I. General patient characteristics

Age	55-78 years (average 74.2 yrs)
M:F	10 : 6
Hypertension	12 (75%)
Diabetes Mellitus	10 (62.5%)
Dyslipidemia	8 (50 %)
Ischemic Heart Disease	2 (12.5 %)
COPD	9 (56.2 %)
Smoking	5 (31.2 %)
BMI > 30	2 (12.5 %)
ICA stenosis $\geq$ 70%	7
ICA stenosis > 90%	9
Bilateral stenosis	2
mRS 2	1
mRS 3	13
mRS 4	2

The neurological symptoms were crescendo-TIA (c-TIA) (n = 7) or stroke in evolution (SIE) or evolving (stuttering) stroke (n=3) or fluctuating neurological deficits (n = 6) corresponding to a contralateral carotid stenosis. The patients' disability was assessed by the use of a modified Rankin Scale (mRS). Those selected for urgent surgery fulfilled the additional following criteria: significant carotid pathology, the absence of cerebral hemorrhage, absence of a deep and fixed neurological deficit (mRS 5), absence of middle cerebral artery occlusion, lesion < 3 cm on CT scan,

and availability of a monitored ICU bed with invasive blood pressure monitoring for post op care. Contraindications for surgery were: mRS 5, presence or suspicion of intracerebral hemorrhage, cerebral lesion > 3 cm, patient unfit for surgery (ASA grade 5) , and middle cerebral artery occlusion.

Prior neurological histories included past stroke (4) and TIA (6) at intervals ranging from 1 month to 6 years before the current presentation. The interval between the onset of symptoms and CEA was 4 – 48 hours (average 8.6 hours). All patients received oral aspirin (325 mg OD) and clopidogrel (75 mg OD) without interruption. A 70-90% stenosis was noted in 7 patients, and more than 90% in 9 patients.

### Operative technique:

All CEA were conducted under general anesthesia to reduce cerebral metabolism. Brain protection was by cooling the patient to 34 C by cooling the OT and a cooling mattress, and packing the head with ice packs. Cerebral flow or brain function monitoring was not done. Standard operative procedures were followed<sup>10</sup>. Meticulous and complete carotid endarterectomy was performed after administration of Intravenous heparin (1mg / Kg). An autologous greater saphenous vein patch was used in all cases to repair the artery. An intraluminal shunt was used in 5 patients. The criteria for the use of a shunt were: stump pressure < 40 mm Hg (2 patients), poor backflow (1 patient), and in patients with occlusion or high-grade stenosis of the opposite internal carotid artery (2 patients).

### Post op protocol:

After urgent CEA all patients were transferred to the intensive care for 24–48 h where invasive blood pressure and central venous pressure monitoring was done and a tight control of blood pressure and blood sugar achieved and maintained with the judicious use of fluids and vasodilators and continuous insulin infusion where indicated .

Postoperative examination by a consultant neurologist was done as soon as the patient was extubated. An immediate duplex ultrasound examination was done in all cases. On follow-up a neurology consult and duplex scan were done at 3 weeks, 6 months and 1 year. A CT / MRI were ordered only if new neurological deficit presented. Lifestyle modification, antiplatelets and statin therapy, control of blood pressure and diabetes mellitus and counseling were given life long.

## RESULT

Ulcerated atheroma was found in all cases (Figure 1). Loose cheesy / creamy atheromatous debris was seen in 5 cases. Fresh clot was extracted in 3 patients (Figure 2- 3). No mortality or neurological morbidity was encountered.

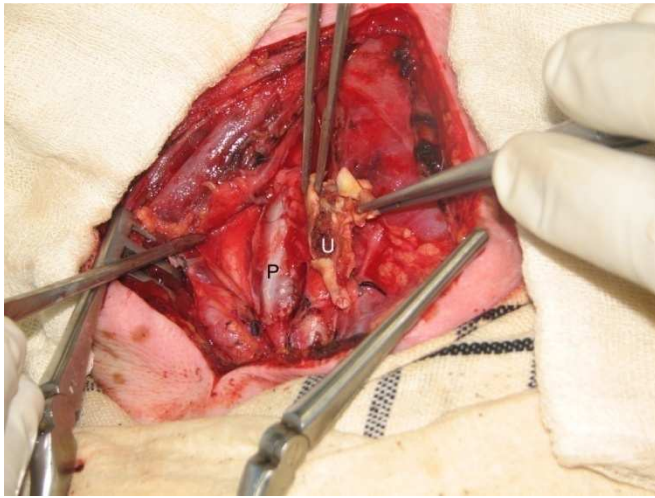


Figure 1: Operative picture showing the ulcerated plaque (U) in the atheroma removed and the saphenous vein patch (P) used to repair the carotid artery

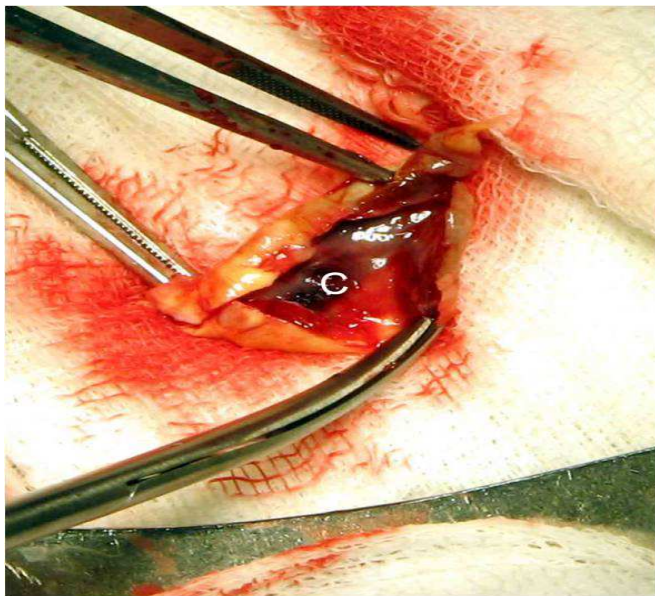


Figure 2 : Atheroma with fresh and organized clot (C)

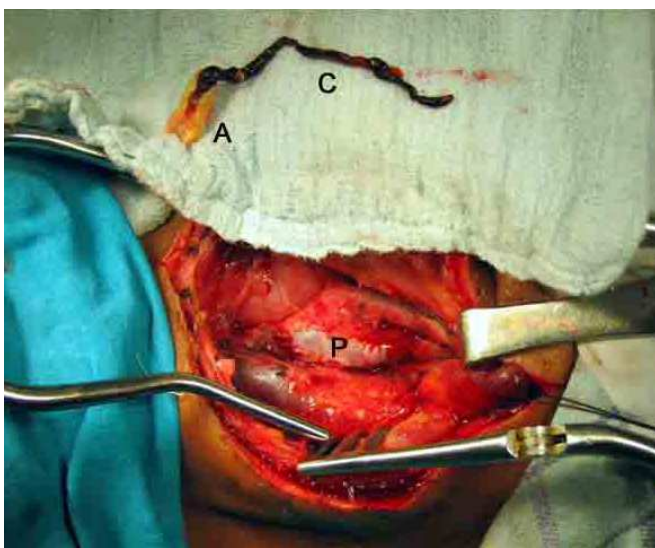


Figure 3 : Atheroma (A) with a long fresh clot (C) . P = vein patch

Following CEA, the neurological deficits improved instantaneously as assessed after extubation to complete recovery in 10 patients – their mRS improved by 2 units. The symptoms of 4 patients improved to non-disabling deficits (mRS improved by 1 unit), and remained unchanged in two. 14/16 patients were discharged within 8 days after admission. The neurologic status after discharge did not deteriorate in any of the patients during follow up, but improved at 6 months further in 4 of the patients who had some residual deficit immediate postop (improvement by 2 units - in 2 in whom there had been no change and 2 in whom there had been a partial improvement).

## DISCUSSION

The prevention of recurrent stroke is one of the foremost goals of urgent treatment of carotid lesions. 30% of all recurrent strokes occur within 30 days.<sup>3,4</sup> The hypothesis of embolization from unstable carotid plaques supports the strategy for urgent carotid endarterectomy. The rationale for urgent carotid endarterectomy in patients presenting with c-TIA, acute stroke or SIE is to improve cerebral perfusion by restoring blood flow to ischemic areas of the brain and to eradicate the source of embolic events secondary to unstable atheromatous plaque in the internal carotid artery.

An interval of four to six weeks after acute stroke has been recommended in the past because of the feared risk of converting a non-hemorrhagic infarct into a hemorrhagic one and consequent extension of the infarcted area in previous studies.<sup>5-7</sup> In contrast to these studies, an increasing number of publications support CEA in the early period after ischemic stroke and confirm the safety and effectiveness of early surgery.<sup>8,9,10</sup> A subgroup analysis of the European Carotid Surgery Trial (ECST) and the North American Symptomatic Carotid Endarterectomy Trial (NASCET) by Rothwell et al<sup>11</sup> showed greater benefit of surgery when performed close to the last symptomatic event. The authors registered an absolute risk reduction of 23% (95% CI 3.8–15.7) in patients with  $\geq 70\%$  stenosis of the ICA operated within two weeks.

In their prospective study comprising 164 subjects, Eckstein et al<sup>8</sup> reported one postoperative cerebral hemorrhage, and neurological improvement in a large number of patients during the first few weeks after surgery. Ferrero et al<sup>12</sup> showed that that early CEA (less than 48 hours) in the acute post stroke phase, for patients clinically selected, did not result in greater complications than when performed delayed or deferred. Furthermore, they stated that the advantage of early CEA is the reduction of recurrent strokes, as untreated patients present a higher incidence of neurological events. Aleksic et al<sup>13</sup> showed that patients with a symptomatic high-grade ICA stenosis can undergo CEA particularly under local anesthesia as soon as possible (< 48 hours) after stroke without an increased complication rate. Bond et al<sup>9</sup> performed a meta-analysis of thirteen studies, showed that early surgery for evolving symptoms, performed in 794 patients, was associated with no additional risk compared to



late CEA. Gorlitzer et al<sup>14</sup> operated on 28 patients with acute stroke at a time duration of 4 days (range 9 hours to 2 weeks) after stroke and found no mortality or morbidity in this group.

In our 16 patients operated within 48 hours of acute neurological event - we had no operative mortality or neurological morbidity and a good recovery of neurological status.

### **Limitations of the study**

The study is limited by the small sample size of the urgent CEA group and by additional biases that are associated with a retrospective analysis. Additional information such as histopathological plaque morphology and follow-up data will be assessed in the future and will provide more information. A study with a larger number of patients and a comparison with non-operative approach would further clarify the issue. The findings of the present study support urgent carotid endarterectomy in patients presenting with acute neurological symptoms. Interdisciplinary cooperation between neurologists, anesthesiologists and vascular surgeons is mandatory to ensure correct decision-making in these clinically demanding patients.

## **CONCLUSION**

Rescue CEA is beneficial for selected patients with stroke in evolution and fluctuating neurological deficits. Careful adherence to selection criteria, judicious intraoperative shunting, intensive care post surgery surveillance and an experienced team are recommended.

## **REFERENCES**

1. European Carotid Surgery Trialists' Collaborative Group. MRC European Carotid Surgery Trial: interim results for symptomatic patients with severe (70–99%) or with mild (0–29%) carotid stenosis. *Lancet*. 1991;337:1235–1243.
2. North American Symptomatic Carotid Endarterectomy Trial Collaborators. Beneficial effect of carotid endarterectomy in symptomatic patients with high-grade carotid stenosis. *N Engl J Med* 1991; 325: 445–453.
3. Sacco RL, Foulkes MA, Mohr JP, Wolf PA, Hier DB, Price TB. Determinants of early recurrence of cerebral infarction: the Stroke Data Bank. *Stroke* 1989; 20: 983–989.
4. Davenport RJ, Dennis MS, Wellwood I, Warlow CP. Complications after acute stroke. *Stroke* 1996; 27: 415–420.
5. Wylie EJ, Hein MF, Adams JE. Intracranial haemorrhage following surgical revascularization for treatment of acute strokes. *J Neurosurg* 1964; 21: 212–218.
6. Rob CG. Operation for acute completed stroke due to thrombosis of the internal carotid artery. *Surgery* 1969; 65: 862–865.
7. Beebe HG. Surgery for acute stroke. *Semin Vasc Surg* 1995; 8: 55–62.
8. Eckstein HH, Ringleb P, Dörfner A, Klemm K, Müller BT, Zegelman M et al . The carotid surgery for ischemic

stroke trial: a prospective observational study on carotid endarterectomy in the early period after ischemic stroke. *J Vasc Surg* 2002; 36: 997–1004.

9. Bond R, Rerkasem K, Rothwell PM. Systematic review of the risks of carotid endarterectomy in relation to the clinical indication for and timing of surgery. *Stroke* 2003; 34: 2290–2301.
10. Pratesi C, Dorigo W, Alessi A, Azas L, Barbanti E, Lombardi R et al . Reducing the risk of intraoperative neurological complications during carotid endarterectomy with early distal control of the internal carotid artery. *Eur J Vasc Endovasc Surg* 2004; 28: 670–673.
11. Rothwell PM, Eliasziw M, Gutnikov SA, Warlow CP, Barnett HJ, Carotid Endarterectomy Trialists Collaboration. Endarterectomy for symptomatic carotid stenosis in relation to clinical subgroups and timing of surgery. *Lancet* 2004; 20(363):915–924.
12. Ferrero E, Ferri M, Viazzo A, Gaggiano A, Ferrero M, Maggio D et al . Early carotid surgery in patients after acute ischemic stroke: is it safe? A retrospective analysis in a single center between early and delayed/deferred carotid surgery on 285 patients. *Ann Vasc Surg*. 2010; 24(7): 890-9.
13. Aleksic M, Rueger MA, Sobesky J, Heckenkamp J, Jacobs AH, Brunkwall J. Immediate CEA for symptomatic carotid disease preferably performed under local anaesthesia is safe. *Vasa* 2007; 36(3): 185-90.
14. Gorlitzer M, Froeschl A, Puschnig D , Locker E . Is the urgent carotid endarterectomy in patients with acute neurological symptoms a safe procedure? *Interact CardioVasc Thorac Surg* 2009; 8: 534-537.

## **CORRESPONDENCE ADDRESS**

**Dr Harinder Singh Bedi** MCh, FIACS (Gold Medalist)  
Head, Dept of CardioVascular & Thoracic Surgery  
Christian Medical College & Hospital  
Room 2200, Ward 14, Brown Road  
Ludhiana – 141008, Punjab, INDIA  
Email: drhsbedicmc@gmail.com,

**Please cite this paper as:** Bedi HS, Pandian JD, Gupta A. Urgent carotid endarterectomy for acute cerebral ischemia. *Inter J Medical Sci Res Prac* 2014; 1 (3): 75-78.

## **ACKNOWLEDGEMENTS**

Nil

## **PEER REVIEW**

Double Blinded externally peer reviewed.

## **CONFLICTS OF INTEREST**

Nil

## **FUNDING**

Nil