

Case Report

Bony suprascapular foramen, a potential site for suprascapular nerve compression: A case report

Shiksha Jangde, Ranjana Arya, Shashi Paikra

Department of Anatomy, Chhattisgarh Institute of Medical Science, Bilaspur, Chhattisgarh, India

ABSTRACT

Suprascapular notch is the site where the suprascapular nerve traverses the upper border of the scapulae under the superior transverse scapular ligament (STSL). The anterior coracoscapular ligament runs in the suprascapular notch, below the STSL. Narrowed bony foramen by complete ossification of these ligaments may be one of the predisposing factors for suprascapular nerve compression. We report the two cases of the bony suprascapular foramen, scapula with complete suprascapular foramen and scapula with suprascapular foramen with the notch. The aim of our case report is to provide knowledge on the variations along the course of suprascapular nerve which is essential to understanding the source of the entrapment syndrome. A thorough knowledge of anatomical variations in the suprascapular region and ossification of suprascapular ligament is important for anatomists, orthopedicians, radiologists, and neurosurgeons to obtain a safe zone which would be useful to avoid iatrogenic nerve lesion and for better diagnosis and management of the nerve entrapment syndrome.

Keywords: Anatomical variations, anterior coracoscapular ligament, entrapment syndrome, superior transverse scapular ligament, suprascapular foramen and notch, and suprascapular nerve

INTRODUCTION

The suprascapular notch is the site where the suprascapular nerve, accompanied by its associated vein, traverses the upper border of the scapulae under the superior transverse scapular ligament (STSL). The anterior coracoscapular ligament (ACSL) runs in the suprascapular notch, below the STSL. The STSL¹ and ACSL² sometimes ossified. Many researchers have reported variations of STSL. This ligament may be calcified, partially or completely ossified, trifurcation and anomalous bands of it.³ Ossification may be influenced by age, mechanical load on ligament, sex, and genetic factors.⁴ Narrowed bony foramen by complete ossification of the suprascapular and ACSLs has gained increased attention over the past few years, because of it being one of the predisposing factors of suprascapular nerve entrapment as well as with an injury to the suprascapular nerve in arthroscopic procedures.⁵⁻⁷ We report the two cases of the bony suprascapular foramen, scapula with complete suprascapular foramen and scapula with suprascapular foramen with the notch. The aim of our

case report is to provide knowledge on the variations along the course of the nerve which is essential to understanding the source of the entrapment syndrome.

CASE REPORT

Two cases of unique anatomical variation in the suprascapular region were found at our institute during the routine osteological studies of human dried scapula of unknown sex in the Department of Anatomy. Both the scapula were observed carefully, and the dimensions of bony suprascapular foramen were recorded in millimeters with the help of metal scale.

In scapula 1, a complete large oval suprascapular foramen of 0.5 mm × 0.8 mm size was present inferior to the bony bar on the right dry scapula (Figure 1). The bony bar bridges the suprascapular notch may be due to complete ossification of STSL.

In scapula 2, a complete small circular foramen of 0.2 mm × 0.3 mm size was present below the thick bony bridge on the

Corresponding Author:

Shiksha Jangde, Department of Anatomy, Chhattisgarh Institute of Medical Science, Bilaspur, Chhattisgarh, India.

E-mail: drshiksha2013@gmail.com

© 2015 International Journal of Medical Science Research and Practice available on www.ijmsrp.com

right dry scapula (Figure 2). Above the bar, wide and blunt J-shaped suprascapular notch exist.

DISCUSSION

Suprascapular notch is located in the superior border of the scapula near to the root of coracoid process. Suprascapular ligament is a strong fibrous band that bridges the suprascapular notch creating a foramen to serves as a passage for suprascapular nerve, which supplies motor branches to supraspinatus, infraspinatus and sensory branches to the rotator cuff muscles, and ligamentous structures of the shoulder and acromioclavicular joint. Notch with foramen was described by Natsis *et al.* as bony bridge, which limit the area of suprascapular notch and divide it into a bony foramen inferiorly and a notch superiorly and it occurs in about 1% of the population.⁸ This bony bridge passing through the middle part of the suprascapular notch reduces the space available for nerve passage (bony bridge decreases the space by about 36.5-38.6%).⁹ A bony bridge lay between them, is created by an ossified ACSL discovered by Avery *et al.*²

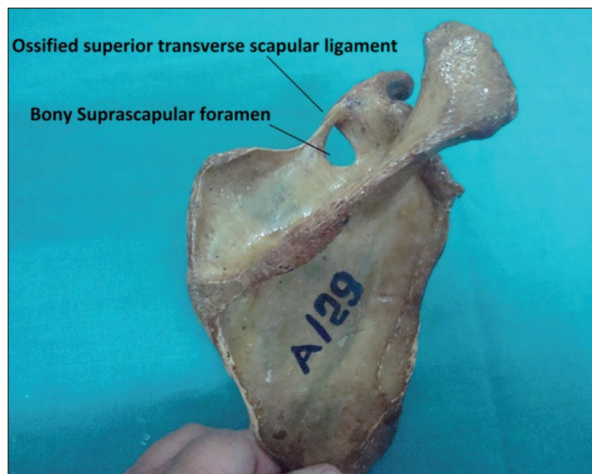


Figure 1: Right scapula with bony suprascapular foramen

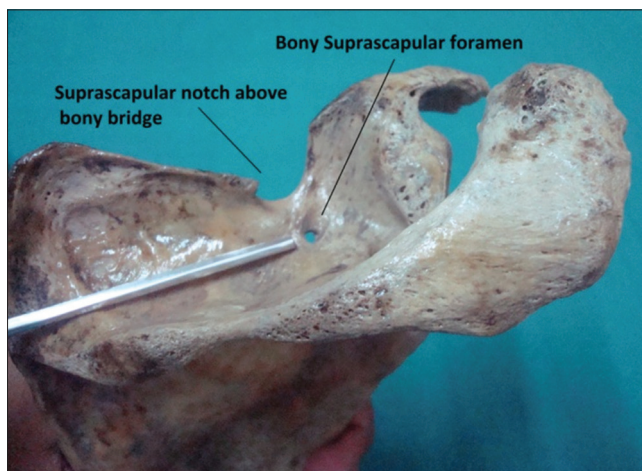


Figure 2: Right scapula with coexisting bony suprascapular foramen and notch

Variation of these ligaments may irritate the suprascapular nerve and gives rise to pain which is deep and poorly localized and because of this the cause of the pain and tenderness is difficult to discover in any individual and the muscle atrophy starts.¹⁰ Narrowing of the suprascapular notch (similar to our case Figure 1) may occur due to calcification, partial or complete ossification of STSL, presence of bony bridge which irritate or compress the suprascapular nerve and give rise to suprascapular nerve entrapment syndrome.¹¹ Furthermore, the shape of the suprascapular notch and excessive movement of the shoulder exerts traction on the suprascapular nerve which leads to its compression against the STSL.¹² Many researchers described the variable incidence of complete ossification of STSL, and it differs from population to population. A case report of complete ossification of STSL was reported by Khan and Das *et al.* in the Indian population.^{13,14} A familial case of calcification of STSL was described by Cohen *et al.* in father and son and both were suffering from entrapment neuropathy of suprascapular nerve.⁵ Suprascapular nerve entrapment is an acquired neuropathy which is secondary to the compression of the nerve, in the bony suprascapular notch.¹⁵

Coexistence of suprascapular notch and suprascapular foramen a rare anatomical variation was found during radiological and anatomical investigations by Polgaj *et al.*¹⁶ Presence of inferior bony bridge caused by the ossification of ACSL decreases the total area of space for the suprascapular nerve in the notch and it may result in suprascapular nerve entrapment (similar to our case Figure 2). A thorough anatomical knowledge of the course of the nerve and its possible sites of entrapment is essential for an early and correct diagnosis and management of the nerve entrapment syndrome.

CONCLUSION

The knowledge of variations in the suprascapular region and ossification of suprascapular ligament is important for anatomists, orthopedicians, radiologists, and neurosurgeons to obtain a safe zone which would be useful to avoid iatrogenic nerve lesion and for better diagnosis and management of the nerve entrapment syndrome.

ACKNOWLEDGMENTS

We would like to acknowledge all the faculty members and technical staff in our department for their advice and assistance.

PEER REVIEW

Externally double blinded, peer reviewed.

CONFLICTS OF INTEREST

Nil

FUNDING

Nil

REFERENCES

1. Standring S, Johnson D, Collins P, Healy JC. Pectoral girdle and upper limb. In: Gray's Anatomy: The Anatomical Basis of Clinical Practice. 40th ed. Philadelphia: Elsevier Churchill Livingstone; 2008. p. 775-906.
2. Avery BW, Pilon FM, Barclay JK. Anterior coracoscapular ligament and suprascapular nerve entrapment. *Clin Anat* 2002;15:383-6.
3. Ticker JB, Djurasovic M, Strauch RJ, April EW, Pollock RG, Flatow EL, *et al.* The incidence of ganglion cysts and other variations in anatomy along the course of the suprascapular nerve. *J Shoulder Elbow Surg* 1998;7:472-8.
4. Mahato RK, Suman P. Ossification of superior transverse scapular ligament: Incidence, etiological factors and clinical relevance. *Int J Health Sci Res* 2013;3:14-21.
5. Cohen SB, Dines DM, Moorman CT. Familial calcification of the superior transverse scapular ligament causing neuropathy. *Clin Orthop Relat Res* 1997;131-5.
6. Polguy M, Jedrzejewski K, Podgórski M, Topol M. Morphometric study of the suprascapular notch: Proposal of classification. *Surg Radiol Anat* 2011;33:781-7.
7. Sinkeet SR, Awori KO, Odula PO, Ogeng'o JA, Mwachaka PM. The suprascapular notch: Its morphology and distance from the glenoid cavity in a Kenyan population. *Folia Morphol (Warsz)* 2010;69:241-5.
8. Natsis K, Totlis T, Tsikaras P, Appell HJ, Skandalakis P, Koebke J. Proposal for classification of the suprascapular notch: A study on 423 dried scapulas. *Clin Anat* 2007;20:135-9.
9. Saritha S. Coexistence of suprascapular notch and suprascapular foramen, a rare anatomical variation and its clinical correlation. *Int J Med Sci Clin Invent* 2014;1:65-8.
10. Thompson WA, Kopell HP. Peripheral entrapment neuropathies of the upper extremity. *N Engl J Med* 1959;260:1261-5.
11. Natsis K, Trifon T, Ioannis G, Konstantinos V, Efthymia P, Prokopios T. A bony bridge within the suprascapular notch. Anatomic study and clinical relevance. *Aristotle Univ Med J* 2008;35:204-11.
12. Soni G, Malik VS, Shulka L, Chhabra S, Gaur N. Morphometric analysis of the suprascapular notch. *Internet J Biol Anthropol* 2012;5:20-7.
13. Khan MA. Complete ossification of the superior transverse scapular ligament in an Indian male adult. *Int J Morphol* 2006;24:195-6.
14. Das S, Suri R, Kapur V. Ossification of superior transverse scapular ligament and its clinical implications. *Sultan Qaboos Univ Med J* 2007;7:157-60.
15. Rengachary SS, Burr D, Lucas S, Hassanein KM, Mohn MP, Matzke H. Suprascapular entrapment neuropathy: A clinical, anatomical, and comparative study. Part 2: Anatomical study. *Neurosurgery* 1979;5:447-51.
16. Polguy M, Jedrzejewski K, Majos A, Topol M. Coexistence of the suprascapular notch and the suprascapular foramen – A rare anatomical variation and a new hypothesis on its formation based on anatomical and radiological studies. *Anat Sci Int* 2013;88:156-62.

How to cite this article: Jangde S, Arya R, Paikra S. Bony suprascapular foramen, a potential site for suprascapular nerve compression: A case report. *Inter J Medical Sci Res Prac* 2015;2(3):159-161.

Received: 12 Jun 2015; **Accepted:** 01 Aug 2015; **Published:** 30 Sep 2015